

# Sartorius muscle pierced by terminal branches of the lateral femoral cutaneous nerve: A case report with brief clinical commentaries

Robert Haładaj<sup>\*</sup>, Ivan Varga

*Institute of Histology and Embryology, Faculty of Medicine, Comenius University in Bratislava, 81372, Bratislava, Slovakia*

## ARTICLE INFO

### Keywords:

Anatomical variations  
Cutaneous branches  
Lateral femoral cutaneous nerve  
Lateral femoral nerve of the thigh  
Sartorius muscle

## ABSTRACT

**Introduction:** Typically, the lateral femoral cutaneous nerve, also known as the lateral cutaneous nerve of the thigh (LCNT), runs under the inguinal ligament near the anterior superior iliac spine, runs anterior to the sartorius muscle and then divides into two terminal branches, i.e., anterior and posterior, which provide sensory innervation to the anterior and lateral thigh. This report describes an unusual anatomic variant in which terminal branches of the LCNT pierced the sartorius muscle.

**Case description:** Dissection involved formalin-fixed right isolated lower limb. The procedure revealed anatomical variation of the LCNT. The nerve's division level into anterior and posterior branches was at the level of the inguinal ligament under the sartorius muscle. The posterior branch of the LCNT was directly adjacent to the anterior superior iliac spine. After a short course, this branch emerged from under the sartorius muscle lateral border 39 mm distally (in a straight line) to the inguinal ligament. The nerve's anterior branch pierced the sartorius muscle. It exited on the anterior surface of the muscle, 72 mm (in a straight line) from the inguinal ligament. The innervation territory of both branches was typical. We found no other anatomical variations of lumbar plexus branches.

**Conclusions:** The LCNT terminal branches may show anatomic variations, which clinicians should consider during neurological assessments of nerve lesions. Deviations from the typical course of nerves should also be kept in mind when conducting surgical interventions.

## 1. Introduction

The lateral femoral cutaneous nerve (also named the lateral cutaneous nerve of the thigh - LCNT) may exhibit numerous anatomical variations that include different levels of nerve origin from the lumbar plexus, variations of the intrapelvic segment of the nerve (including nerve's duplication, early division into terminal branches or anastomoses with adjacent nerves), as well as variations in the course, branching pattern and innervation territory [1–5].

Typically, the LCNT runs under the inguinal ligament, medially to the anterior superior iliac spine, runs anterior to the sartorius muscle, and then divides into two terminal branches, i.e., anterior and posterior, which provide sensory innervation to the skin covering the anterior and lateral thigh (Fig. 1). This report describes an unusual anatomic variant in which terminal branches of the LCNT pierced the sartorius muscle.

## 2. Case description

Dissection involved formalin-fixed right isolated lower limb. The procedure revealed anatomical variation of the LCNT (Fig. 2). The nerve's division level into anterior and posterior branches was at the level of the inguinal ligament. Both branches occupied a medial position to the anterior superior iliac spine. However, LCNT division into its terminal branches was located atypically, i.e., under the sartorius muscle. As a result of such unusual anatomical conditions, the posterior branch of the LCNT was directly adjacent to the anterior superior iliac spine. It emerged from under the sartorius muscle lateral border 39 mm distally (in a straight line) to the inguinal ligament (Fig. 2). The nerve's anterior branch originated below the inguinal ligament, at the anterior superior iliac spine level, then pierced the sartorius muscle and exited on the anterior surface of the muscle, 72 mm (in a straight line) from the inguinal ligament (Fig. 2). The innervation territory of both branches was typical. No other anatomical variations of lumbar plexus branches were found.

<sup>\*</sup> Corresponding author.

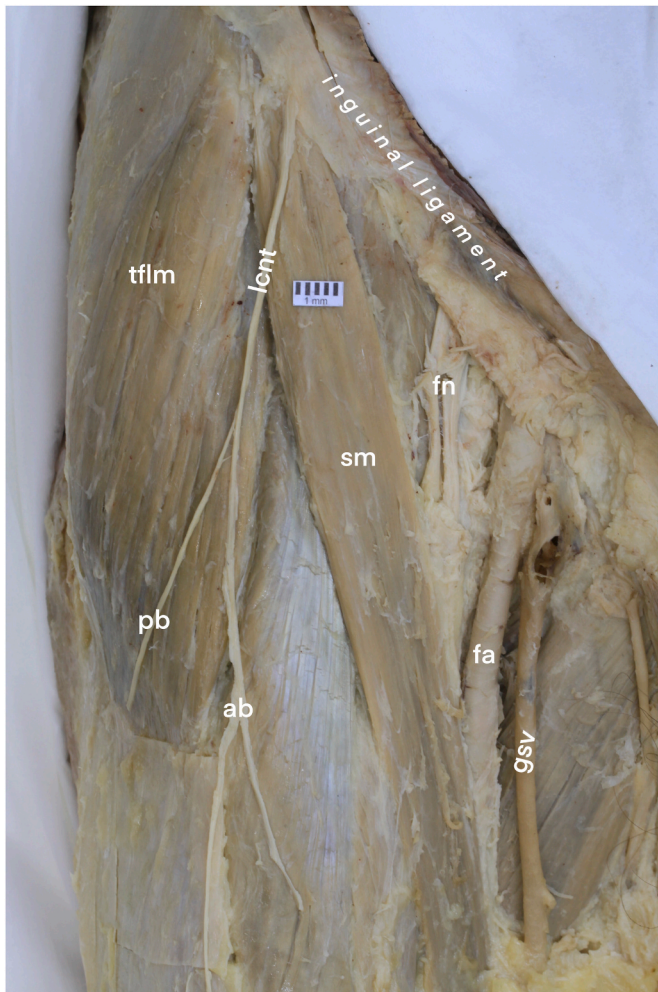
E-mail address: [haladaj1@uniba.sk](mailto:haladaj1@uniba.sk) (R. Haładaj).

<https://doi.org/10.1016/j.tria.2023.100280>

Received 22 December 2023; Received in revised form 28 December 2023; Accepted 29 December 2023

Available online 1 January 2024

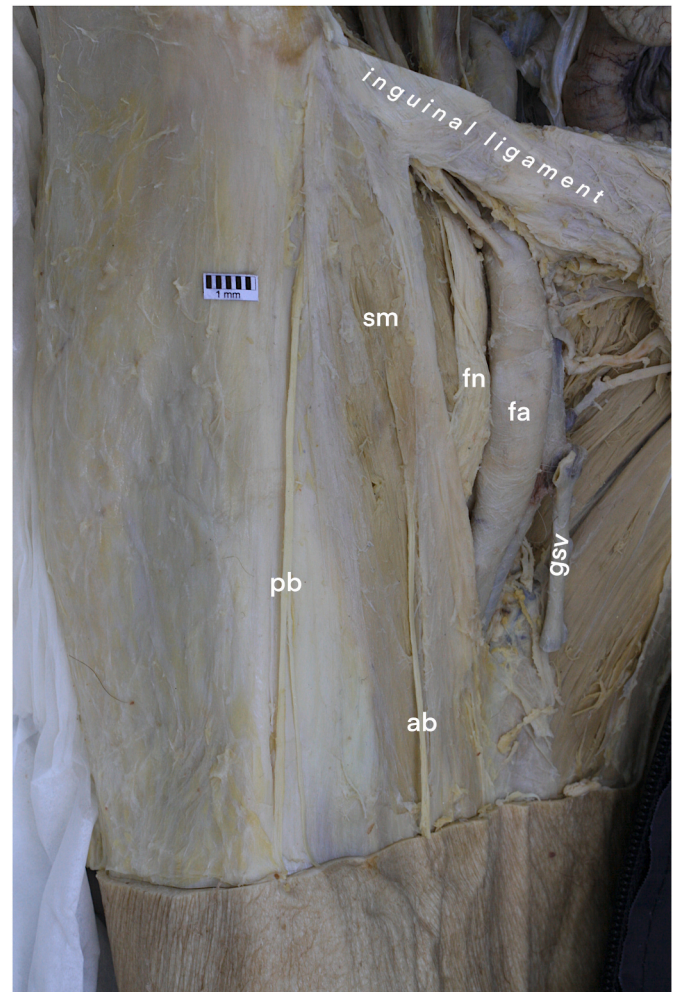
2214-854X/© 2024 The Authors. Published by Elsevier GmbH. This is an open access article under the CC BY license (<http://creativecommons.org/licenses/by/4.0/>).



**Fig. 1.** Normal anatomy of the lateral cutaneous nerve of the thigh (lcnt). Anterior view. The nerve passes under the inguinal ligament, runs on the sartorius muscle's anterior surface, and then divides into anterior (ab) and posterior (pb) terminal branches. fa – femoral artery; fn – femoral nerve; gsv – greater saphenous vein; sm – sartorius muscle; tflm – tensor fasciae latae muscle.

### 3. Discussion

In the medical literature, special attention is paid to the variations of the LCNT related to the anterior superior iliac spine and inguinal ligament. Typically, the LCNT reaches the anterolateral thigh by passing above, below, or piercing the inguinal ligament, most commonly emerging just medial to the anterior superior iliac spine and anterior to the sartorius muscle (Fig. 1). However, numerous variations in LCNT course, and branching patterns may be observed [1–5]. The nerve may run at various distances from the anterior superior iliac spine and can occupy a more medial (or, in rare occasions, more lateral) position than usual [1–5]. One previously reported case presented high division (above the inguinal ligament) of the LCNT; in this case, both branches passed beneath the inguinal ligament at the midpoint of the distance between the anterior superior iliac spine and the femoral artery [6]. The nerve may also course anterior or posterior to, or pass through, the sartorius muscle [1]; relations similar to the last variant were observed in the specimen described in our report. If such a variant occurs, potential entrapment within the muscle is possible. In one of the previous reports, the LCNT pierced the sartorius muscle in 5.8 % of cases. However, the authors did not provide detailed information regarding this variant of topographical anatomy. Relations found in our specimen,



**Fig. 2.** The lateral cutaneous nerve of the thigh divided into anterior (an) and posterior (pb) branches posterior to the sartorius muscle (sm). The posterior branch of the lateral cutaneous nerve of the thigh emerges from under the sartorius muscle and exits on the anterior surface of the muscle. Anterior view. fa – femoral artery; fn – femoral nerve; gsv – greater saphenous vein.

where the anterior LCNT branch pierced the sartorius muscle and the posterior LCNT branch emerged from the lateral border of the sartorius muscle, were not previously reported, according to our best knowledge.

As discussed in our earlier report [6], the topographical relationship between the LCNT and the anterior superior iliac spine vicinity is crucial. With the mean distance between the LCNT and the anterior superior iliac spine estimated at 8.8 mm, the lateral cutaneous femoral nerve courses <2 cm from the medial tip of the anterior superior iliac spine in approximately 90 % of cases [7]. In the specimen presented in this report, the nerve ran right next to the anterior superior iliac spine. Such proximity to the bony prominence and location deep to the sartorius muscle could hypothetically promote nerve compression, for example, during surgical or intensive care patient positioning and surgical procedures [8]. In the case presented in our work, the direct proximity of the LCNT to the anterior superior iliac spine is noteworthy. Such proximity is important because the LCNT can be damaged during Hip Arthroscopy and the Minimally Invasive Anterior Approach for Total Hip Arthroplasty, as well as during harvesting bone graft involving the anterior part of the iliac crest [5,9].

The LCNT division into anterior and posterior branches provides the sensory innervation of the anterior and lateral sides of the thigh. Chronic pressure exerted on the nerve or nerve's entrapment may result in

compression neuropathy and bothersome neurological symptoms in the nerve's sensory innervation territory (tingling, numbness, and burning pain in the outer part of the thigh), referred to as meralgia paresthetica. An area particularly predisposed to nerve injury is the surrounding of the anterior superior iliac spine. As stressed by Brandt et al. [8], pressure damage to the LCNT in the vicinity of the inguinal ligament is assumed to be the main pathomechanism of nerve palsy. Factors that may cause LCNT compression in this area include swelling, obesity, pregnancy, diabetes, tumors, enlarged lymph nodes, mechanical compression, or injuries (including iatrogenic lesions) [4,7–13].

#### 4. Conclusions

The LCNT terminal branches may show anatomic variations, which clinicians should consider during neurological assessments of nerve lesions. Deviations from the typical course of LCNT should also be kept in mind when conducting surgical interventions since the risk is especially posed to the nerve when maneuvers are performed near the anterior superior iliac spine.

#### Ethical statement

The authors state that every effort was made to follow all local and international ethical guidelines and laws that pertain to the use of human cadaveric donors in anatomical research [14].

#### Funding sources

This study was not financially supported.

This research did not receive any specific grant from funding agencies in the public, commercial, or not-for-profit sectors.

#### CRedit authorship contribution statement

**Robert Haladaj:** Writing – review & editing, Writing – original draft, Visualization, Validation, Resources, Project administration, Methodology, Investigation, Formal analysis, Data curation, Conceptualization. **Ivan Varga:** Writing – review & editing, Writing – original draft, Validation, Supervision, Resources, Project administration, Methodology, Investigation, Formal analysis, Data curation, Conceptualization.

#### Declaration of competing interest

None.

#### Acknowledgments

The authors sincerely thank those who donated their bodies to science so that anatomical research could be performed. Results from such research can potentially increase mankind's overall knowledge that can then improve patient care. Therefore, these donors and their families deserve our highest gratitude [15].

#### Appendix A. Supplementary data

Supplementary data to this article can be found online at <https://doi.org/10.1016/j.tria.2023.100280>.

#### References

- [1] R.A. Bergman, A.K. Afifi, R. Miyauchi, Illustrated encyclopedia of human anatomic variation: opus III: nervous system: plexuses. <https://www.anatomyatlases.org/AnatomicVariants/NervousSystem/Text/GenitofemoralNerve.shtml>. (Accessed 28 November 2023).
- [2] R. Haladaj, G. Wysiadecki, V. Macchi, R. de Caro, M. Wojdyn, M. Polguy, M. Topol, Anatomic variations of the lateral femoral cutaneous nerve: remnants of atypical nerve growth pathways revisited by intraneural fascicular dissection and a proposed classification, *World Neurosurg* 118 (2018) e687–e698, <https://doi.org/10.1016/j.wneu.2018.07.021>.
- [3] K.A. Tomaszewski, P. Popieluszko, B.M. Henry, J. Roy, B. Sanna, M.R. Kijek, J. A. Walocha, The surgical anatomy of the lateral femoral cutaneous nerve in the inguinal region: a meta-analysis, *Hernia* 20 (5) (2016) 649–657, <https://doi.org/10.1007/s10029-016-1493-7>.
- [4] N. Mangla, S. Wadhwa, S. Mishra, S. Sural, N. Vasudeva, Cadaveric study of variations in the course of lateral femoral cutaneous nerve: insight to prevent injury, *Medeni Med J* 38 (3) (2023) 172–179, <https://doi.org/10.4274/MMJ.galenos.2023.23356>.
- [5] B. Ray, A.S. D'Souza, B. Kumar, C. Marx, B. Ghosh, N.K. Gupta, A. Marx, Variations in the course and microanatomical study of the lateral femoral cutaneous nerve and its clinical importance, *Clin. Anat.* 23 (8) (2010) 978–984, <https://doi.org/10.1002/ca.21043>.
- [6] R. Haladaj, I. Varga, Coexisting anatomical variation of the lateral femoral cutaneous nerve and genitofemoral nerve: a case report, *Translational Res. Anat.* 34 (2024) 100276, <https://doi.org/10.1016/j.tria.2023.100276>.
- [7] S.H. Lee, K.J. Shin, Y.C. Gil, T.J. Ha, K.S. Koh, W.C. Song, Anatomy of the lateral femoral cutaneous nerve relevant to clinical findings in meralgia paresthetica, *Muscle Nerve* 55 (5) (2017) 646–650, <https://doi.org/10.1002/mus.25382>.
- [8] L. Brandt, S. Albert, K.L. Brandt, Meralgia paraesthetica als Lagerungsschaden : kein voll beherrschbares Risiko [Meralgia paraesthetica as complication of patient positioning : a not fully controllable risk], *Anaesthesiologie* 71 (11) (2022) 858–864, <https://doi.org/10.1007/s00101-022-01213-9>. German.
- [9] J.D. Bartlett, J.E. Lawrence, V. Khanduja, What is the risk posed to the lateral femoral cutaneous nerve during the use of the anterior portal of supine Hip arthroscopy and the minimally invasive anterior Approach for total Hip arthroplasty? *Arthroscopy* 34 (6) (2018) 1833–1840, <https://doi.org/10.1016/j.arthro.2018.01.012>.
- [10] S.C. Lee, L. Ko, C. Gornbein, O.K. Nwawka, Sonographic evaluation of the lateral femoral cutaneous nerve: single-institution experience and pictorial review, *Ultrasound Q.* (2023), <https://doi.org/10.1097/RUQ.0000000000000669>.
- [11] G.C.W. de Ruiter, J.W.A. Oosterhuis, T.F.H. Vissers, A. Kloet, Unusual causes for meralgia paresthetica: systematic review of the literature and single center experience, *Neurosurg. Rev.* 46 (1) (2023) 107, <https://doi.org/10.1007/s10143-023-02023-2>.
- [12] M.G. Grossman, S.A. Ducey, S.S. Nadler, A.S. Levy, Meralgia paresthetica: diagnosis and treatment, *J. Am. Acad. Orthop. Surg.* 9 (5) (2001) 336–344, <https://doi.org/10.5435/00124635-200109000-00007>.
- [13] J.N.T. Solomons, A. Sagir, C. Yazdi, Meralgia Paresthetica, *Curr. Pain Headache Rep.* 26 (7) (2022) 525–531, <https://doi.org/10.1007/s11916-022-01053-7>.
- [14] J. Iwanaga, V. Singh, S. Takeda, J. Ogeng'o, H.J. Kim, J. Morys, K.S. Ravi, D. Ribatti, P.A. Trainor, J.R. Sañudo, N. Apaydin, A. Sharma, H.F. Smith, J. A. Walocha, A.M.S. Hegazy, F. Duparc, F. Paulsen, M. Del Sol, P. Addis, S. Louryan, V.P.S. Fazan, R.K. Boddeti, R.S. Tubbs, Standardized statement for the ethical use of human cadaveric tissues in anatomy research papers: recommendations from Anatomical Journal Editors-in-Chief, *Clin. Anat.* 35 (4) (2021) 526–528, <https://doi.org/10.1002/ca.23849>.
- [15] J. Iwanaga, V. Singh, A. Ohtsuka, Y. Hwang, H.J. Kim, J. Morys, K.S. Ravi, D. Ribatti, P.A. Trainor, J.R. Sañudo, N. Apaydin, G. Şengül, K.H. Albertine, J. A. Walocha, M. Loukas, F. Duparc, F. Paulsen, M. Del Sol, P. Addis, A. Hegazy, R. S. Tubbs, Acknowledging the use of human cadaveric tissues in research papers: recommendations from anatomical journal, *Clin. Anat.* 34 (1) (2021) 2–4, <https://doi.org/10.1002/ca.23671>.